

# Study The Effects of The Pesticide Es-Biothrin on Some Histological Aspects of White Male Rats.

Fakhir M. Alzubaidy

**Abstract-** This study aimed to evaluate the probable histological changes accompanied with the treatment by the pesticide Es-Biothrin. 16 white male rats (three months age) were used. All the rats were exposed daily to the fume of evaporated disks of pesticide Es-Biothrin 5 hours for 35 day. The animals grouped into two groups: the first one treated with 4 disks, and the second treated with 8 disks, also six untreated rats were used as a control group. The rats were killed and the histological study were done for the evaluation of the effects of the pesticide. Results showed different histological changes represented by the presence of pneumonia in the lung of these rats, the infiltration of inflammatory cells, while the trachea had a normal histology in all the animals of the experiment.

## Index Terms-

### 1 INTRODUCTION

Pesticides have numerous beneficial effects. These include crop protection, preservation of food and materials and prevention of vector-borne diseases. For example pesticides may be used in the prevention of malaria, which kills up to 1 million children per year, and for preventing other vector-borne diseases such as dengue, leishmaniasis and Japanese encephalitis.<sup>1</sup>

These modern synthetic insecticides are similar chemically to natural pyrethrins, but pyrethroids are modified to increase stability in the natural environment. They are now widely used in agriculture, in homes and gardens, and for treatment of ectoparasitic disease. There has been increasing use of these agents as use of organophosphate pesticides becomes more restricted.<sup>2</sup> There are relatively few insecticide products registered for

indoor use. Those that are registered are primarily from

one chemical class, the pyrethroids.<sup>3</sup>

Insecticides may persist in house dust, in soil tracked in from outdoors, in carpets, toys, food and furniture. High levels of insecticides have been measured for weeks after professional application, for example indoor pesticide exposure of pyrethroids, and residues of organophosphorus insecticides sprayed in indoor environments have been reported to occur on

floors, carpets, children's toys, furniture, bed covers and in dust.<sup>1,4,5</sup>

High levels of pesticides in carpet dust are a particular concern for young children who, due to their continual exploration of their environments, spend a large amount of time on the floor and have increased hand to mouth activity, resulting in increased exposure to pollutants through dermal and non-dietary ingestion routes.<sup>6,7</sup>

Although pyrethroids have low toxicity, particularly compared to other insecticides, studies have shown that high levels of exposure to pyrethroids may cause significant toxicity and health effects, including acute neurotoxic effects,<sup>8</sup> immunotoxic effects,<sup>9, 10</sup> negative effects on the oxidative status,<sup>11</sup> and negative effects on mammalian reproduction.<sup>12</sup>

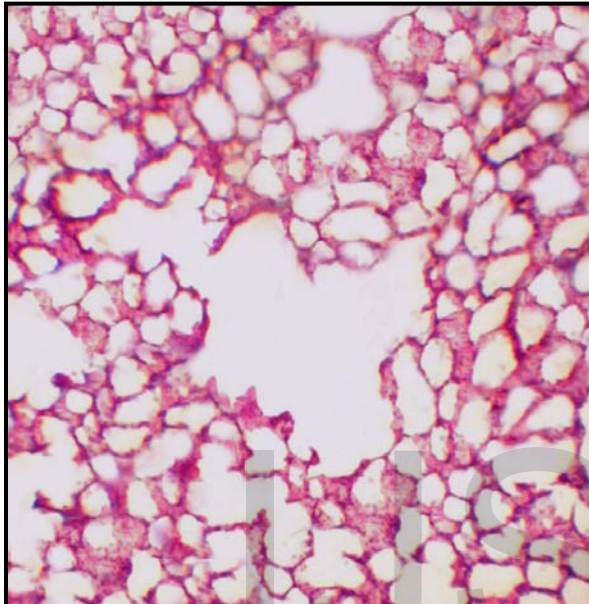
### 2 MATERIALS AND METHODS

Small rooms were designed for this experiment, in order to mimic the normal human living room and the uses of the pesticides in their houses to reflect the probable action of the pesticides. Disks exposed to heat source to release the pesticide fume, this process repeated daily (5 hours) for 35 day. At the end of the experiment, tissues were obtained for the histological study. Ordinary histological sections of paraffin-embedded tissues (5 $\mu$  thick), stained with

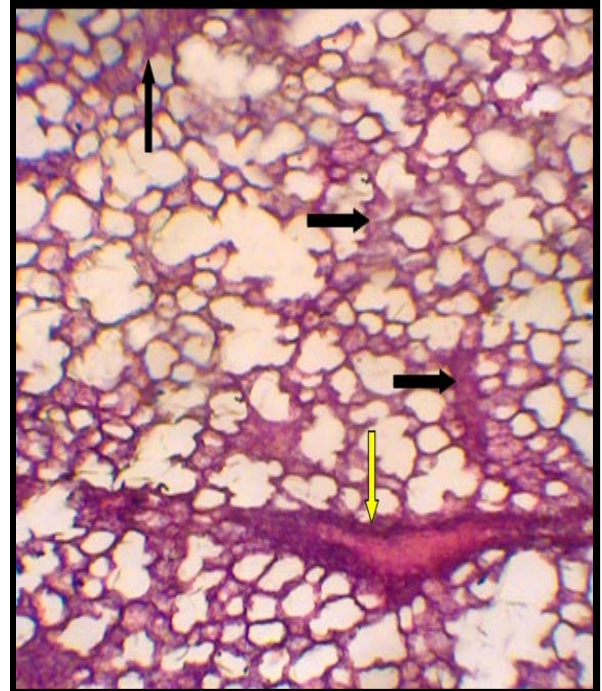
hematoxylin and eosin were performed according to Bancroft and Steven, 1982.<sup>13</sup>

### 3 RESULTS

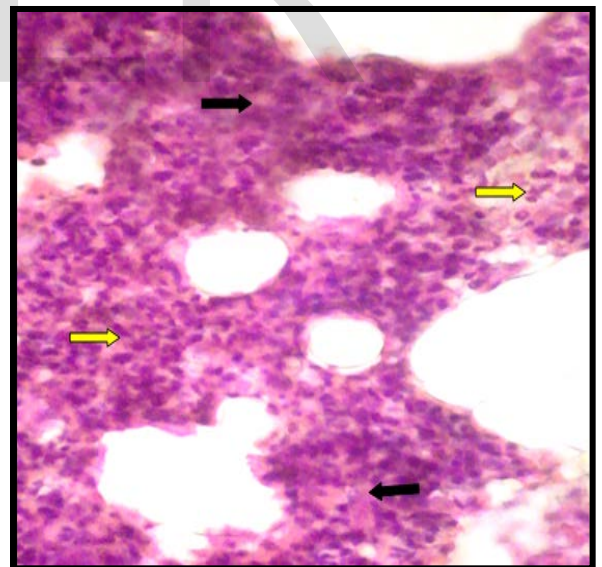
The histological study showed different changes compare with the normal tissues of the control group as follows:



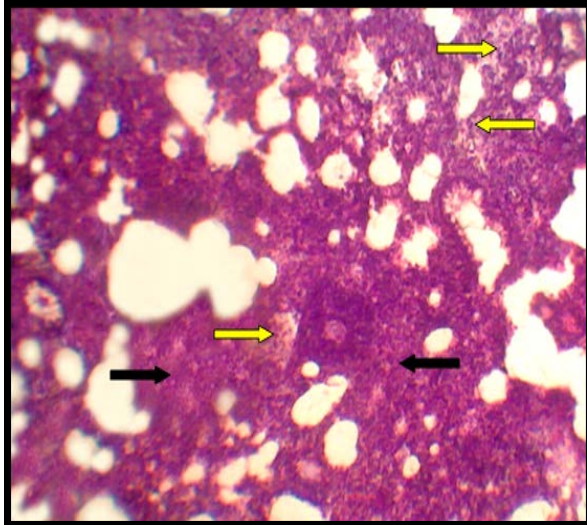
**Figure 1:** Cut Section Through The Lung of the normal rats (control group), showing normal histology.



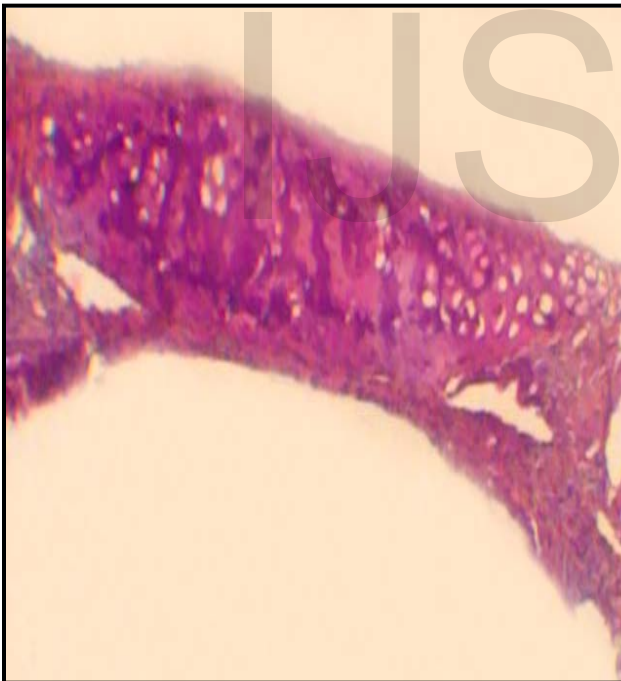**Figure 1:** Cut section through the lung of the rats treated with 4 disks, showing moderate thickening of the alveolar septa (black arrows), and marked peribroncheal chronic inflammatory infiltrate (yellow arrows).



**Figure 2A:** Cut section through the lung of the rats treated with 8 disks, showing marked interstitial chronic inflammatory cell infiltration (yellow arrows) with marked thickening of alveolar septa (interstitial pneumonia) assigned by black arrows.



**Figure 2B:** Cut Section Through The Lung of the rats treated with 8 disks, showing sever interstitial chronic inflammatory cell infiltration (yellow arrows) with marked thickening of alveolar septa (interstitial pneumonia) assigned by black arrows.



**Figure 3:** Cut section through the trachea of the rats, showing normal histology.

#### 4 DISCUSSION

Results showed undesired effects of the pesticide of our experiment on the histology of the lung of both groups (treated with 4 and 8 disks) in compare with the control group, which reflected by the

inflammatory changes ranged from moderate to marked and sever infiltration of inflammatory cells in the interstitial tissue of the lung. These results may be compatible with other studies that referred to the negative effects accompanied with the use of this group of pesticides.<sup>14,15</sup> Also, these effects may be resulted from the oxidative stress that may be caused by the exposure to the pesticide,<sup>11</sup> because this type of pesticide also found to increase the production of reactive oxygen species (ROS) and malondialdehyde (MDA), which is known as a marker of lipid peroxidation (LPO), and decrease antioxidative activity of superoxide dismutase, catalase, and glutathione.<sup>16</sup>

The pesticide of our experiment showed deleterious effects on the histology of the lung but didn't affects the histology of the trachea, this may be explained by the nature of the tissue itself, because the trachea is more protected by the mucous, and composed - mainly- of cartilage.

#### REFERENCES

- [1] Pesticides (2008). Children's Health and the Environment WHO Training Package for the Health Sector. World Health Organization.
- [2] WHO. (2006). Indoor residual spraying - Use of indoor residual spraying for scaling up global malaria control and elimination. WHO/HTM/MAL/.1112.
- [3] Miller, D. M. Bed Bug Treatment Using Insecticides. *Virginia Department of Agriculture and Consumer Services*.
- [4] Trunnelle, K. J. ; Bennett, D. H. ; Tancredi, D. J. ; Gee, S. J. ; Stoecklin-Marois, M. T. ; Hennessy-Burt, T. E. ; Hammock, B. D. ; Schenker, M. B. (2013). Pyrethroids in house dust from the homes of farm worker families in the MICASA study. *Environment International* 61 (2013) 57–63.
- [5] Curl, C. L.; Fenske, R. A. ; Kissel, J. C. ; Shirai, J. H. ; Moate, T. F. ; William Griffith, W. ; Gloria Coronado, G. and Thompson, B. (2002). Evaluation of Take-Home Organophosphorus Pesticide Exposure among Agricultural Workers and Their Children. *Environmental Health Perspectives*.110: 12.
- [6] Moya J, Bearer CF, Etzel RA. Children's behavior and physiology and how it affects



- exposure to environmental contaminants. *Pediatrics* 2004;113:996–1006.
- [7] Gurunathan S, Robson,M.; Freeman,N.; Buckley,B.; Roy,A. ; Meyer,R. ; Bukowski,J. and Paul J. Lioy (1998). Accumulation of chlorpyrifos on residential surfaces and toys accessible to children. *Environ Health Perspect.*106: 9–16.
- [8] Costa, L. G. ; Giordano, G. ; Guizzetti, M. ; Vitalone, A. (2008). Neurotoxicity of pesticides: a brief review. *Front. Biosci.*13: 1240-9.
- [11] Turkez, H. and Aydin, E. (2012).The Effects of Taurine on Permethrin Induced Cytogenetic and Oxidative Damage in Cultured Human Lymphocytes. *Arh Hig Rada Toksikol.* 63:27-34.
- [12] Young, H. A. ; Meeker, J. D. ; Martenies, S. E. ; Zaida I Figueroa, Z. I. ; Dana Boyd Barr, D. B. and Perry, M. J. (2013). Environmental exposure to pyrethroids and sperm sex chromosome disomy: a cross-sectional study. *Environmental Health* 2013, 12:111.
- [13] Bancroft, D. J. and Stevens, A. (1982). *Theory and Practice of Histological Techniques.*2<sup>nd</sup> Edition. Churchill Livingstone. Medical Division of Longman Group Limited.
- [14] Ray, D. E. and Fry, J. R. (2006). A reassessment of the neurotoxicity of the pyrethroid insecticide. *Pharmacol Ther.* 111 (1): 174- 193.
- [15] Sheikh, S. A. ; Nizamani, S. M. ; Jamali, A. A. and Kumbhar, M. I. (2011). Pesticides and associated impact on human health: a case of small farmers in Southern Sindh, Pakistan. *J Pharm Nutr Sci.*1:82-6.
- [16] Hu, F. ; Li, L. ; Wang, C. ; Zhang, Q. ; Zhang, X. and Zhao, M.(2010). Enantioselective induction of oxidative stress by permethrin in rat adrenal pheochromocytoma (PC12) cells. *Environ Toxicol Chem.*29:683-90.
- [9] Gerberding, J. L. (2003). Toxicological Profile for Pyrethrins and Pyrethroids. U.S. Department of Health and Human Services. Public Health Service Agency for Toxic Substances and Disease Registry.
- [10] Prater, M. R. (2002). Immunotoxicity of Dermal Permethrin and Cis-Urocanic Acid: Effects of Chemical Mixtures in Environmental Health.